

John W. Davis  
*Editor*

# Robot-Assisted Radical Prostatectomy

Beyond the Learning Curve

 Springer

Fatih Atug

---

## Introduction

Prostate cancer is the most common non-dermatologic cancer in men and radical prostatectomy is the standard treatment now [1]. In order to reduce the morbidity of open procedure, new techniques have been developed such as laparoscopic radical prostatectomy and recently robotic surgery. Robotic surgery with 3-D view, optical magnification, and 7° moving instruments has developed very rapidly. And today, robot-assisted radical prostatectomy (RARP) is the most popular radical prostatectomy technique with more than 100,000 cases/year in the USA [2]. The utilization of robotic technology to radical prostatectomy operations led surgeons to make more careful, precise, and accurate dissections to see important anatomic structures in order to achieve a negative surgical margin, full continence, and recovery of erectile function.

Apex is the most different and unique part of the prostate, which is the crossroad of functional recovery and oncological control in radical prostatectomy operations. However, there are significant anatomic variations of prostate apex from one individual to another (Fig. 10.1). Every

robotic surgeon should know and realize these anatomic variations and their relationship to urethra, distal sphincter, and neurovascular bundles. An appropriate and careful apical dissection of prostate should include three important steps:

- (a) The last step of prostate removal: cutting the prostate apex at the most precise point to achieve a negative surgical margin.
- (b) Preserving the maximum length of urethra for protecting the urethral sphincter as much as possible.
- (c) If a nerve-sparing procedure was performed, to protect neurovascular bundles by gently dissecting out from apex and the cutting point of urethra.

---

## Anatomic Considerations

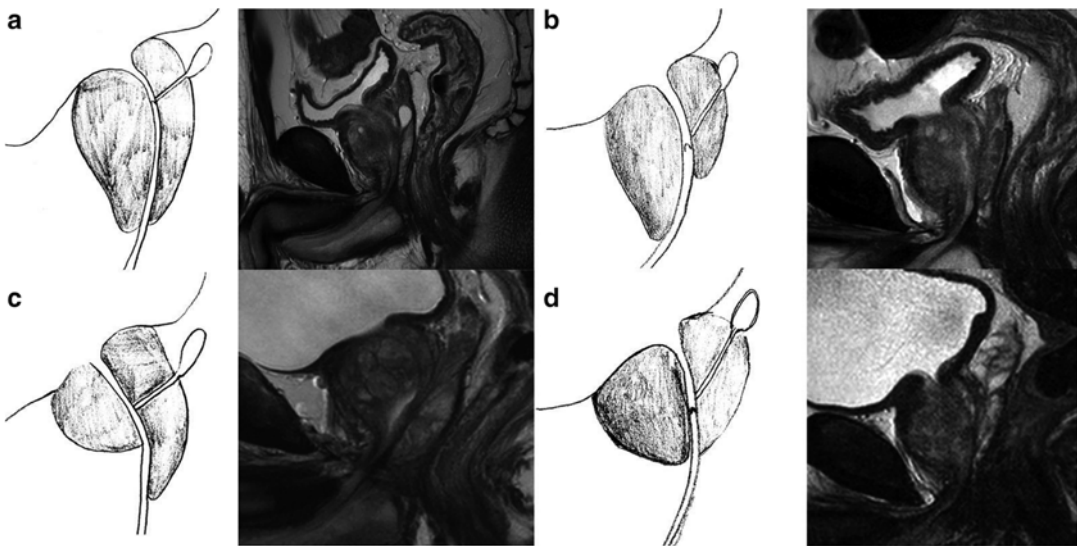
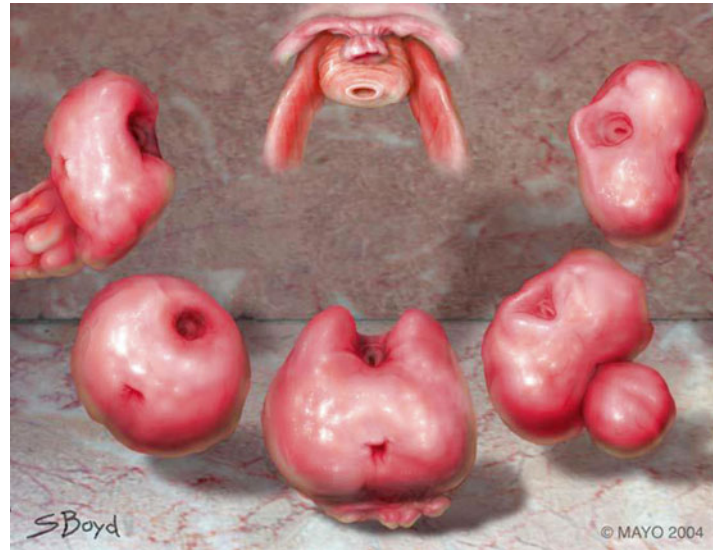*All men created equal but not all prostates are.*

The shape of the prostate differs from one individual to another. The majority of these differences originate from the apical part of the prostate. At puberty, prostate starts to grow and incorporates urethral sphincter. Specifically at the level of prostatic apex, the fibers of the urethral sphincter are partly overlapped by the prostate and covered with it [3–5]. Anatomic and functional studies demonstrated that the length of the functional urethra changes between 1.5 and 2.4 cm and a significant part was located intraprostatically

---

F. Atug (✉)  
Professor of Urology, Istanbul Bilim University  
School of Medicine, Istanbul, Turkey  
e-mail: [fatihatug@hotmail.com](mailto:fatihatug@hotmail.com)

**Fig. 10.1** Different apical shapes of prostates overlapping the urethral sphincter



**Fig. 10.2** Different shapes of prostatic apex by MRI. (a) Apex overlapping the membranous urethra both anteriorly and posteriorly. (b) Apex overlapping membranous

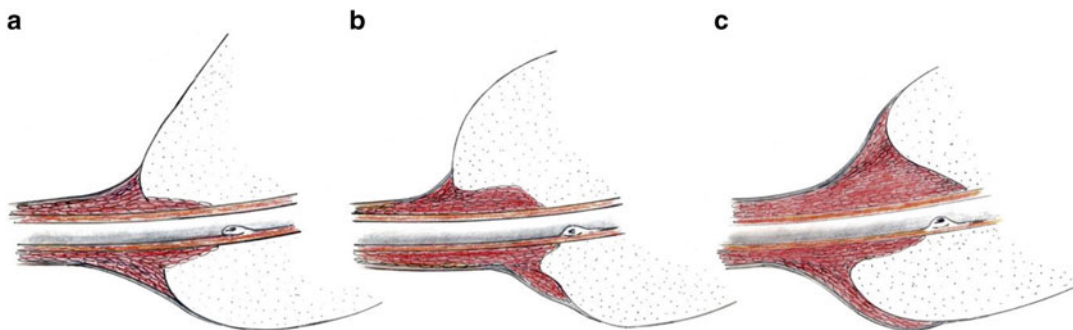
urethra anteriorly. (c) Apex overlapping membranous urethra posteriorly. (d) Apex overlapping membranous urethra (Lee et al.)

between the prostatic apex and the verumontanum [6–12].

The apex may overlap the urethral sphincter circumferentially, symmetrically bilaterally, asymmetrically unilaterally, anteriorly only, and posteriorly only, or can bluntly end above the sphincter (Fig. 10.1) [12, 13]. The shape of the prostate at the apex may vary substantially, directly influencing the length of the urethra after emerging from the apex [14].

Lee et al. reported that circumferential overlap is observed in 38% of all cases, anterior overlap in 25%, posterior overlap in 22%, and no overlap in 15%. Which means that apical overlap or variations can be seen in nearly 85% of patients (Fig. 10.2) [15].

Moreover, significant overlap makes the preservation of urethral sphincter difficult and should be considered during dissection and appropriate transection of the urethra at the apex (Fig. 10.3). When the prostatic parenchyma was covered by



**Fig. 10.3** (a, b) The functional urethra is covered by parenchymal apex tissue. (c) The prostatic apex is covered by urethral sphincter on the ventral and rectal sides

the muscular urethra, there is greater risk of urethral shortening and urinary incontinence [15].

Identifying the exact border of the sphincter overlapped by the prostate intraoperatively is the main surgical difficulty for the surgeon. In addition, preserving the urethral sphincter during apical dissection of the prostate must be balanced with minimizing positive surgical margins.

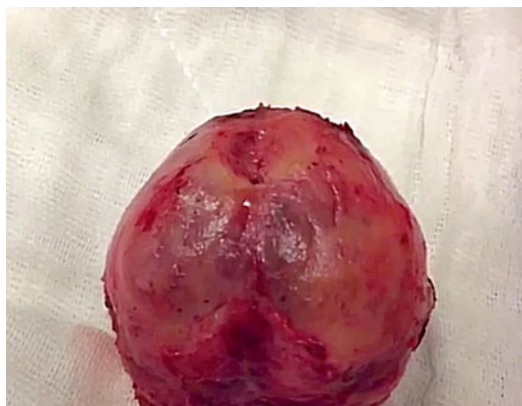## Surgical Technique

**The apical dissection of prostate** is the most difficult part of the radical prostatectomy operation due to several reasons:

- The prostate is located in the deep part of the narrow bony pelvis; moreover the apex of the prostate is located at the deepest and narrowest part of the pelvis.
- There is no real capsule at the level of prostatic apex.
- Prostatic overlap over the urethra exists in majority of patients.
- The ventral part of the apex is covered by the dorsal vascular complex.
- The lateral aspect of the apex is surrounded by neurovascular bundles.

## Surgical Technique

Before starting the apical dissection, the prostate should be free from the bladder neck and neurovascular bundles. Bleeding from neuro-



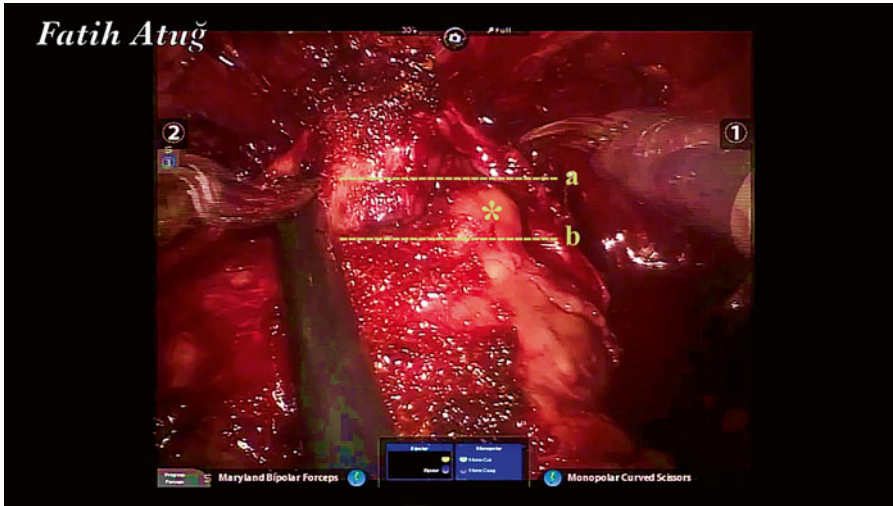
**Fig. 10.4** Prostate apex in a circumferential shape

vascular should be minimal to obtain the ideal visualization. Increasing pneumoperitoneum to 18–20 mmHg prior to transection of the dorsal venous complex may help to obtain a bloodless clear field. After division of DVC, the apex of the prostate and urethra should be inspected very carefully to see the anatomic variations. The apical prostate shape varies significantly from one patient to another; apical overlap or variations can be seen in nearly 85% of patients [16].

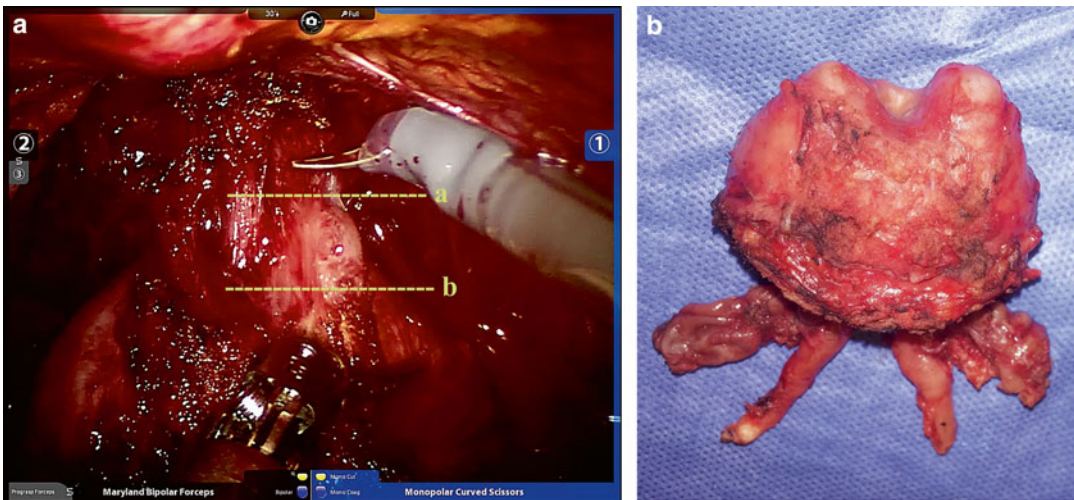
Some different shapes of prostate and variations are given below:

The prostate apex may be in a circumferential shape and end bluntly above the sphincter. There is no overlap of prostate tissue in such patients (Fig. 10.4).

The apex may be asymmetrical unilaterally and protrude over the urethra because of a BPH nodule on one side. In such kind of patients surgeons should be very careful not to leave an apical prostate tissue behind (Fig. 10.5).



**Fig. 10.5** BPH (benign prostatic hyperplasia) nodule on right side of the prostate. (a) Transection of the urethra at the level of BPH nodule. (b) Correct transection line of the urethra. (\*) BPH nodule



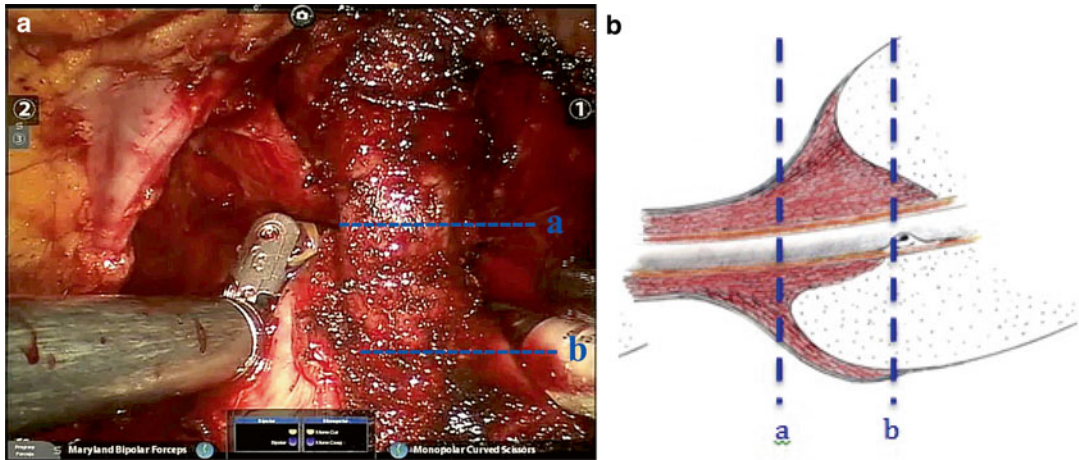
**Fig. 10.6** (a) Prostate apex in a horn shape. Transection of the urethra at the level of the prostate horn. (b) Border of proximal urethra. Prostate specimen of the same patient after the RARP operation

The apical tissue may be in a horn shape on one side or both sides and protrude over the urethra. If the transection is performed at or beyond the horn of the prostate, the residual length of urethra will be short and this may result in delayed return of continence in these patients (Fig. 10.6a, b).

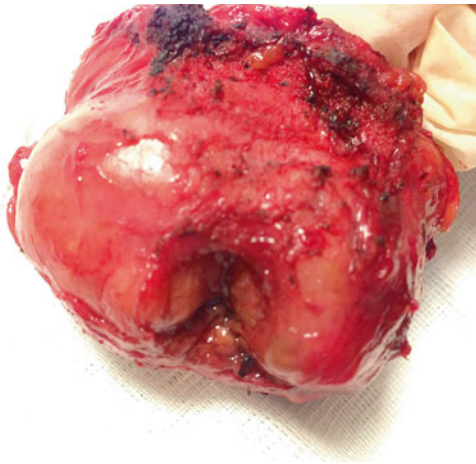It has been demonstrated by several anatomical studies that an important functional part of the urethral sphincter is located intraprostatically between the apex and verumontanum [3, 7, 8, 12, 15]. With the growth of the prostate at puberty, the prostate starts to occupy the sphincteric mus-

cle with covering some part of the sphincter and integrating it within the prostatic tissue [17]. Consequently, depending on the individual apex shape, between 10 and 40% of the functional urethra is covered by parenchymal apex tissue among different patients [10–14, 18].

Moreover, in some patients the prostatic parenchyma may be covered by the muscular urethral sphincter on the anterior side of prostate. Such anatomic variations will cause extra technical difficulty in preservation of distal sphincteric mechanism, Fig. 10.7.



**Fig. 10.7** Prostatic apex is covered by muscular urethral sphincter. (a) Edge of the prostatic apex. (b) Intraprostatic part of the urethra



**Fig. 10.8** The prostate specimen. After removing the intraprostatic part of the urethra, the lateral lobes and verumontanum are clearly seen

The intraprostatically located structures of the sphincter should be appropriately and safely separated from the surrounding prostatic tissue in order to achieve maximum urethral length. After removing the intraprostatically located urethra from the prostate, the lateral lobes of the prostate and verumontanum should be seen clearly, Fig. 10.8.

## Conclusion

Apical dissection of prostate during RARP is the most critical and important part of the radical prostatectomy operations. Dissection of apex will have an intense effect on three important parameters: surgical margin status (apical margin), continence, and sexual function (neurovascular bundles). As every surgeon would agree and know, understanding the complex anatomy of male pelvis and prostate is certainly vital for achieving these goals in RRP operations.

## References

- Center MM, Jemal A, Lortet-Tieulent J, et al. International variation in prostate cancer incidence and mortality rates. *Eur Urol.* 2012;61:1079–92.
- In: Howlader N, Noone AM, Krapcho M, Garshell J, Miller D, Altekruse SF, Kosary CL, Yu M, Ruhl J, Tatalovich Z, Mariotto A, Lewis DR, Chen HS, Feuer EJ, Cronin KA, editors. *SEER Cancer statistics review.* National Cancer Institute; 1975–2012.
- Oelrich TM. The urethral sphincter muscle in the male. *Am J Anat.* 1980;158:229–46.
- Koraitim MM. The male urethral sphincter complex revisited: an anatomical concept and its physiological correlate. *J Urol.* 2008;179:1683–9.

5. Light JK, Rapoll E, Wheeler TM. The striated urethral sphincter: muscle fibre types and distribution in the prostatic capsule. *Br J Urol.* 1997;79:539–42.
6. Groutz A, Blaivas JG, Chaikin DC, et al. The pathophysiology of postradical prostatectomy incontinence: a clinical and video urodynamic study. *J Urol.* 2000;163:1767–70.
7. Hammerer P, Huland H. Urodynamic evaluation of changes in urinary control after radical retropubic prostatectomy. *J Urol.* 1997;157:233–6.
8. Myers RP, Cahill DR, Devine RM, King BF. Anatomy of radical prostatectomy as defined by magnetic resonance imaging. *J Urol.* 1998;159:2148–58.
9. Nguyen L, Jhaveri J, Tewari A. Surgical technique to overcome anatomical shortcoming: balancing post-prostatectomy continence outcomes of urethral sphincter lengths on preoperative magnetic resonance imaging. *J Urol.* 2008;179:1907–11.
10. Paparel P, Akin O, Sandhu JS, et al. Recovery of urinary continence after radical prostatectomy: association with urethral length and urethral fibrosis measured by preoperative and postoperative endorectal magnetic resonance imaging. *Eur Urol.* 2009;55:629–39.
11. Walz J, Burnett AL, Costello AJ, et al. A critical analysis of the current knowledge of surgical anatomy related to optimization of cancer control and preservation of continence and erection in candidates for radical prostatectomy. *Eur Urol.* 2010;57:179–92.
12. Myers RP. Practical surgical anatomy for radical prostatectomy. *Urol Clin North Am.* 2001;28:473–90.
13. Myers RP. Male urethral sphincter anatomy and radical prostatectomy. *Urol Clin North Am.* 1991;18:211–27.
14. Myers RP, Villers A. Anatomic considerations in radical prostatectomy. In: Kirby RS, Partin AW, Feneley M, Parsons JK, editors. *Prostate cancer; principles and practice*, vol. 1. Abingdon, UK: Taylor & Francis; 2006. p. 701–13.
15. Lee SE, Byun SS, Lee HJ, et al. Impact of variations in prostatic apex shape on early recovery of urinary continence after radical retropubic prostatectomy. *Urology.* 2006;68:137–41.
16. Lee H, Kim K, Hwang SI, Lee HJ, Byun SS, Lee SE, Hong SK. Impact of prostatic apical shape and protrusion on early recovery of continence after robot-assisted radical prostatectomy. *Urology.* 2014;84(4):844–9.
17. Wallner C, Dabhoiwala NF, DeRuiter MC, Lamers WH. The anatomical components of urinary continence. *Eur Urol.* 2009;55:932–44.
18. Schlomm T, Heinzer H, Steuber T, Salomon G, Engel O, Michl U, Haese A, Graefen M, Huland H. Full functional-length urethral sphincter preservation during radical prostatectomy. *Eur Urol.* 2011;60(2):320–9.